


## ORIGINAL ARTICLE

# Hysterosalpingo-foam sonography (HyFoSy): Tolerability, safety and the occurrence of pregnancy post-procedure

Keisuke Tanaka<sup>1</sup> , Jackie Chua<sup>2,3</sup>, Robert Cincotta<sup>2,3</sup>, Emma L. Ballard<sup>4</sup> and Gregory Duncombe<sup>2,5</sup>

<sup>1</sup>Department of Obstetrics and Gynaecology, Gold Coast University Hospital, Southport, Australia

<sup>2</sup>Queensland Ultrasound for Women, Spring Hill, Australia

<sup>3</sup>Department of Maternal Fetal Medicine, Mater Mother's Hospital, South Brisbane, Australia

<sup>4</sup>QIMR Berghofer Medical Research Institute, Herston, Australia

<sup>5</sup>Centre for Advanced Prenatal Care, Royal Brisbane and Women's Hospital, Herston, Australia

*Correspondence:* Keisuke Tanaka, Department of Obstetrics and Gynaecology, Gold Coast University Hospital, 1 Hospital Boulevard, Southport QLD 4215, Australia. Email: keisuke.tanaka@trainee.ranzcog.edu.au

*Conflict of interest:* The authors report no conflicts of interest.

Received: 5 June 2017;

Accepted: 16 August 2017

**Background:** Fallopian tube patency testing is an essential part of infertility evaluation. Hysterosalpingo-contrast sonography (HyCoSy) has been described as reliable, well tolerated and safe compared to other modalities such as laparoscopy and a dye test or hysterosalpingography. Limited availability of the previously used contrast has led to the introduction of a foam contrast agent as an alternative.

**Aims:** To assess the tolerability, safety and occurrence of pregnancy post-procedure of hysterosalpingo-foam sonography (HyFoSy).

**Materials and Methods:** A retrospective cohort study of women who had a HyFoSy at Queensland Ultrasound for Women from March 2013 to February 2015. A questionnaire was sent to their referring doctor to identify any complications or subsequent pregnancies with or without artificial reproductive technology (ART) within six months of the HyFoSy.

**Results:** Of 200 women, four cases were abandoned due to difficulty introducing the intracervical catheter, severe discomfort or a vasovagal episode. Response from referring doctors for 155 women reported no post-procedural complication. One hundred and eleven women were followed up for at least six months. Twenty-four out of 59 women (40.7%) who had ART and 24 out of 52 women (46.2%) who did not have ART conceived. Fifty percent of women who were nulligravida at the time of investigation, found to have at least one patent fallopian tube, whose partner had a normal semen analysis, spontaneously conceived within the time of follow up.

**Conclusions:** HyFoSy is well tolerated and safe. A preponderance of pregnancies in the first month after HyFoSy suggests that a therapeutic effect may exist.

## KEYWORDS

fallopian tube, hysterosalpingo-contrast sonography, hysterosalpingo-foam sonography, infertility, ultrasound

## INTRODUCTION

Five percent to 15% of couples experience infertility.<sup>1</sup> Female infertility accounts for approximately 65% of cases and 40% of those

are due to tubal and pelvic pathology.<sup>2</sup> Investigation to assess fallopian tube patency is an essential part of management. These studies include laparoscopy with a dye test, hysterosalpingography and hysterosalpingo-contrast sonography (HyCoSy). HyCoSy has been

reported to be as reliable as laparoscopic techniques or hysterosalpingography in the assessment of tubal patency and uterine morphology. The use of HyCoSy overcomes major drawbacks such as hospitalization, radiation exposure, anaesthesia and use of iodinated contrast media of the related procedures.<sup>3</sup> Limited availability of commonly used echogenic contrast medium for HyCoSy such as Echovist® (Schering AG, Berlin, Germany) or Levovist® (Schering AG, Berlin, Germany) has led the introduction of a foam as an alternative. This alternate procedure was first described in 2011, and termed hysterosalpingo-foam sonography or HyFoSy,<sup>4</sup> and has been reported to be accurate in the diagnosis of tubal patency when compared to chromopertubation during laparoscopy.<sup>5</sup>

HyCoSy has been reported as being well tolerated and safe. Savelli *et al.* reported that it had a low mean pain numeric rating scale.<sup>6</sup> They reported a 0.8% incidence of severe vasovagal reaction, with no late complications and no hospital admissions. Marci *et al.* also reported a low mean pain numeric rating scale, a 4.1% incidence of mild vasovagal reaction, no severe vasovagal reaction and no late complications.<sup>7</sup>

Improvements in conception rate after tubal flushing with hysterosalpingogram has been reported for half a century.<sup>8</sup> Although a randomised control trial comparing water-soluble contrast medium with no flushing did not demonstrate a significant difference in pregnancy rate,<sup>9</sup> tubal flushing with oil-soluble contrast medium has been reported to be associated with a higher pregnancy rate than no flushing<sup>10</sup> and a higher pregnancy rate than water-soluble contrast media in a recent large multi-centre randomised controlled trial.<sup>11</sup> A Cochrane meta-analysis reported a pregnancy rate between 29% and 55% with tubal flushing with oil-soluble contrast media compared to 17% with no intervention.<sup>12</sup> Possible mechanisms of action of lipiodol an oil-soluble contrast medium, rather than a tubal flushing, have been reported, which include a change in production of cytokines by peritoneal macrophages, an inhibition of sperm phagocytosis by peritoneal mast cells or macrophages, and osteopontin downregulation in the endometrium.<sup>13</sup> In this study we aim to assess the tolerability, safety and occurrence of pregnancy following the use of the HyFoSy technique to assess tubal patency.

## MATERIALS AND METHODS

ExEm-gel® (Gynaecologiq BV, Delft, The Netherlands) is a foam which has been used as an ultrasound contrast agent at Queensland Ultrasound for Women (QUFW) since March 2013 for tubal patency investigations as part of fertility workup. QUFW is a private ultrasound practice with ultrasonologist subspecialists reporting and performing all procedures. A HyFoSy procedure is performed between days 2–9 of the menstrual period as per protocol. After the initial transabdominal examination, a urine pregnancy test is obtained to exclude pregnancy prior to the transvaginal assessment. This is done to identify any potential pelvic pathology. The vagina and cervix is prepped with chlorhexidine, then a balloon catheter (Rocket HSG &

Sonohistogram catheter with integral wire stylet® (Rocket Medical plc, Washington, The UK) is inserted and inflated within the endometrial cavity to secure its placement. Under ultrasound guidance, saline is infused to visualise the uterine cavity for any intracavity pathology. Foam is prepared by an assistant as per instructions, by mixing 10 mL of ExEm-gel® with 10 mL of purified water. The foam is then injected via the balloon catheter to assess patency of the fallopian tubes.

All women who visit QUFW are asked to fill a consent form for their data to be used for auditing or research. A search on Viewpoint® (GE Healthcare, Chicago, Illinois, United States), the statistical and reporting package used at QUFW, identified all the women who had a HyFoSy from March 2013 to February 2015. A questionnaire was sent to their referring doctor to identify any side effects or complications from the HyFoSy. Additional information sought included conception within six months of the procedure, spontaneous or otherwise, time to conception and the results of the partner's semen analysis.

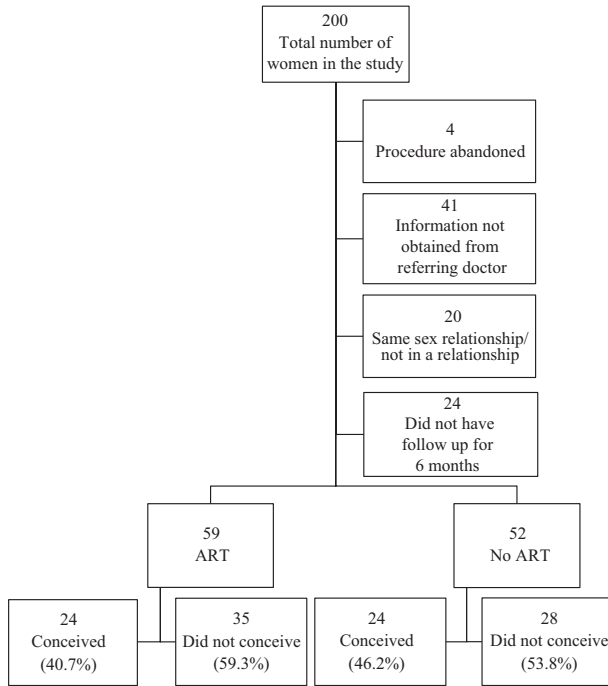
Data were analysed using SPSS version 23 (IBM, Armonk, NY, USA). Categorical variables were examined using the Pearson's  $\chi^2$  test or Fisher's exact test where at least 20% of the expected frequencies were less than five. Continuous variables were examined using Student's *t*-test or Mann-Whitney *U*-test when values were not normally distributed.

This study was assessed by the office of research ethics, the University of Queensland, and judged to meet the National Statement definition of a project that is exempt from full ethics review.

## RESULTS

Two hundred and thirteen women had HyFoSy performed at QUFW during the study period. Thirteen women did not consent for their information to be used in research; therefore, the total number of patients in this study is 200. The procedure was unable to be performed in four women (2.0%). The catheter could not be inserted through the cervix in two women and the other two women complained of significant discomfort or experienced a vasovagal episode leading to the procedure being abandoned (Fig. 1).

We were able to obtain information for 155 women from their referring doctors. The mean age of the patients was 32.7 years (range 21–43). Ninety-four women (60.6%) were nulligravidae, 124 women (80.0%) were nulliparous and 31 women (20.0%) were multiparous. Bilateral fallopian tubal patency was observed in 142 women (91.6%) and unilateral fallopian tubal patency was observed in nine women (5.8%). Four women (2.6%) were found to have bilateral fallopian tubal occlusion. Twenty women had HyFoSy to assess suitability for artificial insemination with donor sperm as they were in a same-sex relationship or not in a relationship. The indication for HyFoSy for the remainder of the women was infertility or fertility concern. The median duration of unprotected intercourse at the time of HyFoSy was 14.0 months (range 3–120).



**FIGURE 1** Flowchart of study participants.

None of the 155 women reported any side effects of HyFoSy to their referring doctors at their follow-up appointment. Excluding 20 women in a same-sex relationship or not in a relationship, and 24 women who were not followed up for six months after HyFoSy, of the remaining 111 women, ART was performed in 59 women and 52 women did not have ART within six months after HyFoSy. Comparison between women who received ART and those who did not receive ART within six months of HyFoSy was made (Table 1). Women who received ART were on average slightly younger (31.7 years) than women who did not (33.3 years;  $P = 0.042$ ). There was no significant difference in gravida, parity, length of subfertility, tubal patency and partner's semen status between those who received or did not receive ART. Twenty-four women (40.7%) conceived with ART and 24 women (46.2%) conceived spontaneously ( $P = 0.56$ ).

The group of 52 women who did not receive ART were evaluated on the basis of whether the conception was spontaneous or not within six months of the procedure (Table 2). Those who conceived had a shorter median length of subfertility (12.0 vs 18.0 months) compared to those who did not conceive ( $P = 0.002$ ). There was no significant difference in age, gravida, parity, tubal patency and partner's semen status between those who conceived or did not conceive.

Subgroup analysis was performed on a group of 26 nulligravidae women with at least one Fallopian tube patent who did not have ART within six months after HyFoSy, and their partner had a normal semen analysis. Thirteen women (50.0%) conceived spontaneously and 13 women did not conceive. There was no significant difference in age, length of subfertility or tubal patency between those who conceived or did not conceive (Table 3). One

**TABLE 1** Comparison between women who received ART and those who did not receive ART within six months of HyFoSy

	No ART	ART	<i>P</i> -value
	<i>n</i> (%)	<i>n</i> (%)	
	<i>n</i> = 52	<i>n</i> = 59	
Age, mean (SD)	33.3 (4.3)	31.7 (4.0)	0.042
Multigravida	20 (38.5%)	23 (39.0%)	0.96
Multiparity	10 (19.2%)	10 (16.9%)	0.76
Length of subfertility, months, median (IQR)	12.5 (11.3–23.0)	17.0 (12.0–24.0)	0.29
Tubal patency			1.00
Bilateral patency	47 (90.4%)	53 (89.8%)	
Unilateral patency	4 (7.7%)	4 (6.8%)	
Bilateral occlusion	1 (1.9%)	2 (3.4%)	
Semen analysis ( <i>n</i> = 106)			0.18
Normal	44 (91.7%)	48 (82.8%)	
Abnormal	4 (8.3%)	10 (17.2%)	
Conception within six months	24 (46.2%)	24 (40.7%)	0.56

ART, artificial reproductive technology; HyFoSy, hysterosalpingo-foam sonography.

**TABLE 2** Comparison between women who conceived and those who did not conceive without ART within six months of HyFoSy

	Did not conceive	Conceived	<i>P</i> -value
	<i>n</i> (%)	<i>n</i> (%)	
	<i>n</i> = 28	<i>n</i> = 24	
Age, mean (SD)	34.2 (3.8)	32.2 (4.7)	0.099
Multigravida	9 (32.1%)	11 (45.8%)	0.31
Multiparity	3 (10.7%)	7 (29.2%)	0.16
Length of subfertility, months, median (IQR)	18.0 (12.0–24.0)	12.0 (8.0–13.5)	0.002
Tubal patency			1.00
Bilateral patency	25 (89.3%)	22 (91.7%)	
Unilateral patency	2 (7.1%)	2 (8.3%)	
Bilateral occlusion	1 (3.6%)	0 (0.0%)	
Semen analysis ( <i>n</i> = 48)			0.61
Normal	23 (88.5%)	21 (95.5%)	
Abnormal	3 (11.5%)	1 (4.5%)	

ART, artificial reproductive technology; HyFoSy, hysterosalpingo-foam sonography.

**TABLE 3** Subgroup analysis of women who did not have ART and were nulligravidae, had at least one fallopian tube patent and their partner had normal semen analysis.

	Did not conceive	Conceived	P-value
	n (%)	n (%)	
	(n = 13)	(n = 13)	
Age, mean (SD)	32.7 (3.8)	31.2 (3.3)	0.31
Length of subfertility, median (IQR)	16 (11.5–24.0)	12.0 (8.8–16.8)	0.14
Tubal patency			1.00
Bilateral patency	12 (92.3%)	13 (100.0%)	
Unilateral patency	1 (7.7%)	0 (0.0%)	

ART, artificial reproductive technology; IQR, interquartile range.

woman who did not conceive had unilateral tubal patency and all the other women had bilateral tubal patency. With respect of timing the conception from HyFoSy examination, six women (46.1%) conceived within a month, two women (15.4%) conceived within two months, three women (23.1%) conceived within three months and two women (15.4%) conceived within five months.

## DISCUSSION

Our study has shown that HyFoSy is well tolerated and the procedure was completed in 98% of cases. Inability to insert the catheter through the cervical canal and severe patient discomfort to the point of vasovagal episodes were the main reasons the procedures were abandoned. In previous studies when the perception of pain during HyFoSy was evaluated, 30% of women reported the same level of discomfort or pain for HyFoSy compared to transvaginal ultrasound scan and 7.9% of women considered HyFoSy to be 'really painful'.<sup>14</sup> Furthermore, in a randomised control trial comparing HyFoSy to water-soluble contrast hysterosalpingogram, women stated statistically significantly lower pain scores from HyFoSy on a visual analogue scale.<sup>15</sup> The relatively high tolerability observed in this study thus supports the use of HyFoSy.

HyFoSy as a tubal patency examination has the main advantage of no obvious serious side effects.<sup>4</sup> This was demonstrated with our study. The safety aspect of ExEm-gel® which contains glycerol, hydroxyethyl cellulose and purified water has been reported.<sup>16</sup> Glycerol and hydroxyethyl cellulose have been used for intra-vascular, intra-gastrointestinal, intra-peritoneal, intra-uterine and topical applications, and no allergic reactions have been described. Furthermore, animal tests did not find any systemic genotoxicity or influence on blastocyst development. This is another advantage of HyFoSy; in comparison, the laparoscopy and dye test carries both surgical and anaesthetic risks and hysterosalpingography requires an iodinated contrast which has the risk of an allergic reaction.

There was no significant difference in pregnancy rate between women who received ART and those who did not within six months of HyFoSy, despite our finding that women who received ART were significantly younger. It is possible that referring doctors have recommended ART to those who were thought to be unlikely to spontaneously conceive. Referring doctors might have provided women with some fertility timing advice or lifestyle changes to maximise a chance of spontaneous pregnancy. Moreover, when women present to our practice for HyFoSy, we advise them regarding timing and frequency of intercourse in relation to their menstrual cycle.

We have analysed the effects of HyFoSy on pregnancy rate by studying nulligravidae women with at least one fallopian tube patent with a partner with a normal semen analysis who did not attempt ART. Fifty percent of these women conceived spontaneously within six months of HyFoSy, although it should be noted that only 26 women fulfilled the criteria. However, this is higher than a previously reported 30% pregnancy rate within six months of HyFoSy,<sup>17</sup> or 22.2% pregnancy rate within six months of HyCoSy.<sup>18</sup> Oil-soluble contrast medium has been reported to have a higher rate of pregnancy than women who had no intervention in the recent Cochrane review,<sup>12</sup> and this is largely based on the findings from the randomised controlled study with 158 women with unexplained infertility conducted by Johnson *et al.*<sup>10</sup> They reported that lipiodol flushing resulted in a 38.4% pregnancy rate at six months compared to 16.5% with no intervention (relative risk 2.33, 95% confidence interval 1.33–4.08). A limitation of this study is the lack of a control group; a larger study including a control group would be required to confirm that the pregnancy rate is higher using this method.

Previous studies have reported that the median time between the HyFoSy procedure and the detection of the pregnancy was three months (range 2–12),<sup>4</sup> and the mean time between HyCoSy and the time of conception was 75 days.<sup>18</sup> These are similar to our finding of the mean time of 2.2 months. Moreover, Giugliano *et al.* found that 45% of who women conceived within 180 days of HyCoSy did so in the first 30 days,<sup>18</sup> while our study found similar numbers in that 46.1% of women who conceived within six months of HyFoSy did so in the first month. Giugliano *et al.* stated that the strong correlation between the pregnancy rate and the timing from HyCoSy confirmed the role of HyCoSy favouring spontaneous pregnancy during the same menstrual cycle in which it was carried out.

In conclusion, HyFoSy is a well-tolerated and safe procedure. Our findings suggest that a significant proportion of women conceive spontaneously following HyFoSy. Although our data suggest that a therapeutic effect may exist, caution should be used as to the effects of HyFoSy on conception and pregnancy within a short timeframe following HyFoSy.

## ACKNOWLEDGEMENTS

The authors wish to thank referring obstetricians and gynaecologists, including Dr Benjamin Bopp, Dr Andrew Cary, Dr Andrew

Davidson, Dr Suzan Elharmeel, Dr Michael Flynn, Dr Rachel Green, Dr Marianne Ilbery, Dr Irving Korman, Dr Eva Kretowicz, Dr Tim O'Dowd, Dr Glenn Sterling, Dr Gary Swift and Dr Yen Yared for providing the data for this study.

## REFERENCES

1. Boivin J, Bunting L, Collins JA *et al.* International estimates of infertility prevalence and treatment-seeking: potential need and demand for infertility medical care. *Hum Reprod* 2007; **22**: 1506–1512.
2. Dun EC, Nezhat CH. Tubal factor infertility: diagnosis and management in the era of assisted reproductive technology. *Obstet Gynecol Clin North Am* 2012; **39**: 551–566.
3. Lo Monte G, Capobianco G, Piva I *et al.* Hysterosalpingo contrast sonography (HyCoSy): let's make the point!. *Arch Gynecol Obstet* 2015; **291**(1): 19–30.
4. Emanuel MH, van Vliet M, Weber M, Exalto N. First experiences with hysterosalpingo-foam sonography (HyFoSy) for office tubal patency testing. *Hum Reprod* 2012; **27**(1): 114–117.
5. Van Schoubroeck D, Van den Bosch T, Meuleman C *et al.* The use of a new gel foam for the evaluation of tubal patency. *Gynecol Obstet Invest* 2013; **75**: 152–156.
6. Savelli L, Pollastri P, Guerrini M *et al.* Tolerability, side effects, and complications of hysterosalpingocontrast sonography (HyCoSy). *Fertil Steril* 2009; **92**: 1481–1486.
7. Marci R, Marcucci I, Marcucci AA *et al.* Hysterosalpingocontrast sonography (HyCoSy): evaluation of the pain perception, side effects and complications. *BMC Med Imaging* 2013; **13**: 28.
8. Weir WC, Weir DR. Therapeutic value of salpingograms in infertility. *Fertil Steril* 1951; **2**: 514–522.
9. Lindborg L, Thorburn J, Bergh C, Strandell A. Influence of HyCoSy on spontaneous pregnancy: a randomized controlled trial. *Hum Reprod* 2009; **24**: 1075–1079.
10. Johnson NP, Farquhar CM, Hadden WE *et al.* The FLUSH trial - flushing with lipiodol for unexplained (and endometriosis-related) subfertility by hysterosalpingography: a randomised trial. *Hum Reprod* 2004; **19**: 2043–2051.
11. Dreyer K, van Rijswijk J, Mijatovic V *et al.* Oil-based or water-based contrast for hysterosalpingography in infertile women. *N Engl J Med* 2017; **376**: 2043–2052.
12. Mohiyiddeen L, Hardiman A, Fitzgerald C *et al.* Tubal flushing for subfertility (Review). *Cochrane Database Syst Rev* 2015; **5**: CD003718.
13. Jonson NP. Review of lipiodol treatment for infertility - an innovative treatment for endometriosis-related infertility? *Aust N Z J Obstet Gynaecol* 2014; **54**: 9–12.
14. Van Schoubroeck D, Van den Bosch T, Amey L *et al.* Pain during Fallopian-tube patency testing by hysterosalpingo-foam sonography. *Ultrasound Obstet Gynecol* 2015; **45**: 346–350.
15. Dreyer K, Out R, Hompes PG *et al.* Hysterosalpingo-foam sonography, a less painful procedure for tubal patency testing during fertility workup compared with (serial) hysterosalpingography: a randomized controlled trial. *Fertil Steril* 2014; **102**: 821–825.
16. Exalto N, Stassen M, Emanuel MH. Safety aspects and side-effects of ExEm-gel and foam for uterine cavity distension and tubal patency testing. *Reprod Biomed Online* 2014; **29**: 534–540.
17. Exacoustos C, Tiberio F, Szabolcs B *et al.* Can tubal flushing with hysterosalpingo-foam sonography (HyFoSy) media increase women's chances of pregnancy? *J Minim Invasive Gynecol* 2015; **22**: S238.
18. Giugliano E, Cagnazzo E, Bazzan E *et al.* Hysterosalpingo-contrast sonography: is possible to quantify the therapeutic effect of a diagnostic test? *Clin Exp Reprod Med* 2012; **39**: 161–165.